

Popliteal Artery to Tibial Plateau Distance at the Knee Level: A Radiological Study to Assess Injury Risks in Osteoarthritic Knees Using Dual Source Dual Energy CT Scan

Ezamin, A. R.^{1*}, Hasyma, A. H.¹, Suppiah, S.¹, Suraini, M. S.¹, Arifaizad, A.², Paisal, Hussin.², Nasir, M. Nizlan.², Sidique, S. F.³ and Hariati, J.⁴

¹Department of Imaging, Faculty of Medicine and Health Sciences, Universiti Putra Malaysia, 43600 UPM, Serdang, Selangor, Malaysia

²Department of Orthopaedic, Faculty of Medicine and Health Sciences, Universiti Putra Malaysia, 43600 UPM, Serdang, Selangor, Malaysia

³Faculty of Economics and Management, Universiti Putra Malaysia, 43400 UPM Serdang, Selangor, Malaysia

⁴Putrajaya Hospital, Precinct 7, 62250 Putrajaya, Malaysia

ABSTRACT

Popliteal artery injury is the most disastrous intraoperative complication during total knee replacement. This study aims to determine the mean distance between the popliteal artery (PA) and the tibial plateau in normal and osteoarthritic patients who underwent Dual Energy CT Angiography (CTA) of the lower limb. Materials and Methods: All CTA lower limb examinations from January 2013 to October 2014 were retrospectively reviewed. The distance between the PA the tibial plateau distance and the thickness of popliteus muscle were electronically measured. We used modified Kellgren and Lawrence's Classification to grade the osteoarthritis in patients who underwent CT examinations regardless of symptoms. Results: There were a total of 126 patients who underwent CTA (93 males and 33 females). 54 of them were Malays, 47 Indians, and 24 Chinese. The mean age of patients was 58 years (range 16 to 92). The mean PA-to-tibial plateau distance was 9.9 mm for the right lower limb (range 2.5 mm to 17.2 mm) and 10.24 mm for the left (range 5.5 mm to 15.4 mm). There were no significant correlations between PA-to-tibial plateau distance with osteoarthritis grade, age, gender, and racial origin ($P > 0.05$); however, there was a positive correlation between PA-to-tibial plateau distances with popliteus muscle thickness ($P = 0.000$). Conclusion:

Osteoarthritic condition in the knee does not reduce the popliteal artery to the tibial plateau distance. Hence, a higher osteoarthritic grade does not impose additional risks with regards to popliteal artery to tibial plateau distance, with relatively similar arterial injury risks compared to normal knees.

Keywords: Radiology, popliteal artery, osteoarthritic

Article history:

Received: 16 June 2016

Accepted: 20 December 2016

E-mail addresses:

drezahar@gmail.com (Ezamin, A. R.),

hasyma@upm.edu.my (Hasyma, A. H.),

subapriya@upm.edu.my (Suppiah, S.),

surainimd@yahoo.com.my (Suraini, M. S.),

aripmd@gmail.com (Arifaizad, A.),

shaufique@gmail.com (Sidique, S. F.),

hariati@gmail.com (Hariati, J.)

*Corresponding Author

INTRODUCTION

Popliteal artery injury is a disastrous intraoperative complication when doing total knee replacement (TKR). The incidence rate of popliteal artery injury following TKR is rare; up to 0.57% based on a recent study using Nationwide Inpatient Sample (NIS) of 1,120,508 in the United States from 1998 to 2009 (Ko et al., 2014). This study also stated that the rate of popliteal artery injury was greatly increased during the revision of the surgery; however, the causes for the popliteal artery injury were not revealed.

Another smaller scale study suggested that of arterial injury patients post-total hip and knee arthroplasty, 50% tend to take legal action later. This should be an eye opener to the operating surgeon dealing with such cases (Parvizi et al., 2008). Several mechanisms have been proposed as the cause of popliteal artery injury perioperatively: atheromatous plaque embolism, thrombosis as a consequence of intimal tears and slow flow induced by tourniquet release of contracture or traction. Thus leading to intimal tear or compression of the artery against bony or hard structure, and lastly iatrogenic injury caused by instruments, traction, or implants (Butt et al., 2010). Some authors suggested that the artery moves further posteriorly by knee flexion (Shiomi et al., 2001; Yoo et al., 2009; Mitsuhiro et al., 2011). It has become a popular practice for the surgeons to flex the knee 90 degrees, presumably to avoid arterial complications. However, it is still debatable whether flexion of the knee will be a protection from direct arterial complication during the knee surgery. Other authors suggested popliteal artery is not always away from the tibia during flexion (Zaidi et al., 1995; Smith et al., 1999; Shetty et al., 2003; Eriksson et al., 2010). CT angiography (CTA) allows precise mapping of the arterial component and soft tissue of the bilateral lower limbs eloquently. Our study has measured the distance of the popliteal artery and the tibial plateau of normal and osteoarthritic (OA) patients who underwent routine CTA of the lower limb.

MATERIAL AND METHODS

All lower limb CTA images from January 2013 to October 2014 were retrospectively reviewed. Incomplete data or poor images were excluded in this study. Standard local CTA of the lower limb protocol was used in this study, using CTA with 128-DECT (dual energy) CT scanner (Somatom Sensation Flash, Siemens Medical Solutions). Consent for CTA was taken in each contrast study in our facility prior to the CTA examination. CT scanning was done in supine position with the knee extended. Images were retrieved from the local database server (PACS) and viewed using BARCO diagnostic display monitor and using GE- centricity version 2.0-2004 software (General Electric software).

We measured the shortest distance of PA to tibial plateau and the popliteus muscle thickness in axial 5 x 5 mm slice thickness with knee at 0-degree flexion using electronic callipers GE Centricity version 2.0 (Fig 1). The measurements at each parameter were taken three times.

The average measurement was taken as the final measurement. For osteoarthritis grading, we used the coronal view 5 mm slice perpendicular to the axial plane and also AP projection of the topography. We used Kellgren and Lawrence's grading scale for osteoarthritis as the basis of Osteoarthritis (OA) grading. Grade 0: no radiographic features of OA are present; grade 1: doubtful joint space narrowing (JSN) and possible osteophytic lipping; grade 2: definite osteophytes and possible JSN on anteroposterior weight-bearing radiograph; grade 3: multiple osteophytes, definite JSN, sclerosis, possible bony deformity; grade 4: large osteophytes, marked JSN, severe sclerosis and definite bony deformity (Kellgren & Lawrence, 1957). Poor quality images with poor visualisation of the popliteal artery due to any other reasons were excluded in our study. These data were then compiled into the Microsoft excel spreadsheet and later analysed using SPSS version 20. Spearman correlation $P = 0.000$ is considered as significant.

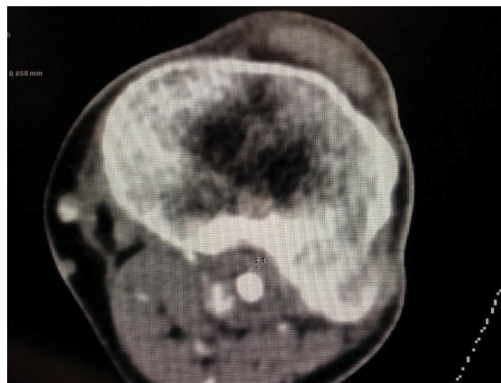


Figure 1. The axial view at the level of tibial plateau. Line number 1 shows the shortest distance of PA to tibial plateau and line 2 shows the popliteus muscle thickness.

RESULTS

A total of 126 patients underwent CTA (93 males and 33 females). 54 patients in this study were Malays, 47 Indians, and 24 Chinese. The mean age of the patients was 58 years old (range 16 to 92). The mean PA-to-tibial plateau distance is 9.9 mm for the right lower limb (range 2.5 mm to 17.2 mm) and 10.24 mm for the left (range 5.5 mm to 15.4 mm). Table 1 further illustrates the results. There were no significant correlations between PA-to-tibial plateau distance with osteoarthritis grade, age, gender, and racial origin ($P > 0.000$); however, there were positive correlations between PA-to-tibial plateau distances with popliteus muscle thickness ($P = 0.000$). There was also significant correlation between the right PA to tibial plateau distance with the left PA to tibial plateau distance ($P = 0.000$).

Table 1

Results obtained in the study. *rgrad* = right OA grade, *rdis* = right PA to tibial plateau distance, *rmuscle* = right popliteus muscle thickness, *lgrad* = left OA grade, *ldis* = left PA to tibial plateau distance, *lmusc* = left popliteus muscle thickness.

Variable	Obs	Mean	Std deviation	Min	Max
rgrad	126	2.31746	1.306297	0	5
lgrad	126	2.198413	1.344737	0	5
rdis	124	9.933871	2.660579	2.5	17.2
ldis	119	10.24118	2.329996	5.5	15.4
rmusc	124	7.614516	1.929897	1.5	13.8
lmusc	119	8.097479	2.053953	4	13
Age	126	58.19048	15.14924	16	92
Gender	126	.7380952	.4414263	0	1

DISCUSSION

To our knowledge, based on the scientific literature written in English e in PUBMED and Google Scholar. The study finds a correlation between mean popliteal artery and tibial plateau distance. . It is known that Computed Tomography (CT) is sensitive and accurate in estimating osteophytes formation compared with plain radiography (Chan et al., 1991). Overestimation or underestimation was expected when determining the joint space especially if the CTA was done on a non-weight bearing supine position. We tried to limit over/underestimation of the osteoarthritis grading, based on Kellgren Lawrence’s grading system, by correlating the reconstructive coronal view of CT images and the topography images acquired during CTA.

There are multiple ways to study the popliteal artery distance to the proximal tibia. In-vivo ultrasound (Farrington et al., 1999; Eriksson et al., 2010) and MRI knee images (Smith et al., 1999; Shiomu et al., 2001; Sanz-Pérez M et al., 2015) were the popular methods of investigation; until recently, cadaveric anatomical study with CT angiographic analysis (Bisicchia et al., 2014) was also being used.

CTA has the advantage of reproducibility, and reliability when measuring the popliteal artery distance without external compression, unlike using ultrasound. The ultrasound probe may compress the popliteal area structure, thus causing the popliteal artery to be nearer to the bony prominence during the examination, especially if it is done in prone position, thus skewing the actual measurement. The biggest disadvantages of CTA imaging modality are often due to contrast media complications and radiation burden concern.

There was no significant correlation between PA-to-tibial plateau distances with osteoarthritis grades in our study. This finding may suggest that osteoarthritic condition in the knee does not reduce the popliteal artery to the tibial plateau distance. Hence, a higher osteoarthritic grade does not impose additional risks with regards to popliteal artery to tibial plateau distance, with relatively similar arterial injury risks compared to normal knees.

There was no significant correlation seen in the PA to tibial plateau distances across h age, gender, and racial origin in our study. Contrary to our finding, Sanz-Pérez (2015) has suggested that the distance of the posterior of the external meniscus to the popliteal artery is significantly greater in male gender ($P = 0.006$). In the same study, it was also stated that there was no correlation between the distance from the posterior wall of the external meniscus to the popliteal artery with height, weight, BMI, diameter of tibial plateau, and AP diameter of the external meniscus (Sanz-Pérez et al., 2015).

A positive correlation between PA-to-tibial plateau distances with popliteus muscle thickness ($P = 0.000$) was seen in our study probably can be explained that the muscle is sandwiched in between the posterior tibia and the popliteal artery. The larger popliteus muscle mass thus will increase the distance of the mean PA-to-tibial plateau distance.

Our study showed that the mean PA-to-tibial plateau distance is 9.9 mm for the right lower limb and 10.24 mm for the left knee. This is not very different from the findings of other studies. Eriksson (2010) showed that the PA to the tibial plateau distance in osteoarthritic patients using ultrasound bilaterally in full knee extension is 8 mm. Sanz-Pérez (2015) suggested that the minimum distance from the posterior wall of the external meniscus to the popliteal artery was 10.01 mm. A study by Farrington (1999), using ultrasound doppler in 0 degree in osteoarthritic patient preoperatively, found that the position of PA in the arthritic knee is less than 1 cm. Bisicchia (2015) suggested the median as the shortest distance PA to the proximal tibial osteotomy zone is 9.6 mm. Yang (2011) suggested the average distance between the tibial cortex and the neurovascular structure was less than 10 mm. The shortest distance found in the literature was seen by Mitsuhiro (2011), using ultrasound as the mode of examination. The mean distance in the study control knees was 4.9 ± 0.3 mm at 0° flexion. Kim (2010) in a cadaveric anatomical study and lateral plain X-ray findings suggested that at 2 cm below the joint line, the mean distance at 0° was 6.2 ± 4.2 mm.

We did not find any presence of aberrant anterior tibial artery in our series although the incidence in a study by Klecker (2008) had reported the incidence to be as high as 2.1%.

The study population does not represent the real normal population because most of our patients already suffer from lower limb arterial disease. Concern over the effects of radiation exposure during CTA examination limits the feasibility of doing exploratory prospective study for normal subjects.

ACKNOWLEDGEMENTS

The authors would like to thank hospital Serdang radiology staff for their cooperation in data acquisition and mentoring.

Disclosure:

The authors did not receive any payments, services from a third party for any aspect in this study.

REFERENCES

- Bisicchia, S., Rosso, F., Pizzimenti, M. A., Rungprai, C., Goetz, J. E., & Amendola, A. (2015). Injury risk to extraosseous knee vasculature during osteotomies: a cadaveric study with CT and dissection analysis. *Clinical Orthopaedics and Related Research*, 473(3), 1030-1039.
- Butt, U., Samuel, R., Sahu, A., Butt, I. S., Johnson, D. S., & Turner, P. G. (2010). Arterial injury in total knee arthroplasty. *Journal of arthroplasty*, 25(8), 1311-1318.
- Chan, W. P., Lang, P., Stevens, M. P., Sack, K., Majumdar, S., Stoller, D. W., & Genant, H. K. (1991). Osteoarthritis of the knee: comparison of radiography, CT, and MR imaging to assess extent and severity. *American journal of roentgenology*, 157(4), 799-806.
- Eriksson, K., & Bartlett, J. (2010). Popliteal artery-tibial plateau relationship before and after total knee replacement: a prospective ultrasound study. *Knee Surgery, Sports Traumatology, Arthroscopy*, 18(7), 967-970.
- Farrington, W. J., Charnley, G. J., Harries, S. R., Fox, B. M., Sharp, R., & Hughes, P. M. (1999). The position of the popliteal artery in the arthritic knee. *The Journal of arthroplasty*, 14(7), 800-802.
- Kellgren, J. H., & Lawrence, J. S. (1957). Radiological assessment of osteo-arthritis. *Annals of the rheumatic diseases*, 16(4), 494-502.
- Kim, J., Allaire, R., & Harner, C. D. (2010). Vascular Safety During High Tibial Osteotomy A Cadaveric Angiographic Study. *The American journal of sports medicine*, 38(4), 810-815.
- Klecker, R. J., Winalski, C. S., Aliabadi, P., & Minas, T. (2008). The Aberrant Anterior Tibial Artery Magnetic Resonance Appearance, Prevalence, and Surgical Implications. *The American journal of sports medicine*, 36(4), 720-727.
- Ko, L. J. M., DeHart, M. L., Yoo, J. U., & Huff, T. W. (2014). Popliteal artery injury associated with total knee arthroplasty: trends, costs and risk factors. *The Journal of arthroplasty*, 29(6), 1181-1184.
- Parvizi, J., Pulido, L., Slenker, N., Macgibeny, M., Purtill, J. J., & Rothman, R. H. (2008). Vascular injuries after total joint arthroplasty. *The Journal of arthroplasty*, 23(8), 1115-1121.
- Sanz-Pérez, M., García-Germán, D., Ruiz-Díaz, J., Navas-Pernía, I., & Campo-Loarte, J. (2015). Localización de la arteria poplítea y su relación con el riesgo vascular en la sutura del cuerno posterior del menisco externo. *Revista Española de Cirugía Ortopédica y Traumatología*, 59(3), 165-171.
- Shetty, A. A., Tindall, A. J., Qureshi, F., Divekar, M., & Fernando, K. W. K. (2003). The effect of knee flexion on the popliteal artery and its surgical significance. *Bone and Joint Journal*, 85(2), 218-222.
- Shiomi, J., Takahashi, T., Imazato, S., & Yamamoto, H. (2001). Flexion of the knee increases the distance between the popliteal artery and the proximal tibia: MRI measurements in 15 volunteers. *Acta Orthopaedica Scandinavica*, 72(6), 626-628.
- Smith, P. N., Gelinas, J., Kennedy, K., Thain, L., Rorabeck, C. H., & Bourne, R. B. (1999). Popliteal Vessels in Knee Surgery A Magnetic Resonance Imaging Study. *Clinical orthopaedics and related research*, 367, 158-164.
- Takeda, M., Ishii, Y., Noguchi, H., & Sato, J. (2011). Change in the Position of the Popliteal Artery with Knee Flexion after Total Knee Arthroplasty. *Journal of Bone and Joint Surgery*, 93(21), e123.
- Yang, D., Zhou, Y., Tang, Q., Xu, H., & Yang, X. (2011). Anatomical relationship between the proximal tibia and posterior neurovascular structures: a safe zone for surgeries involving the proximal tibia. *The Journal of arthroplasty*, 26(7), 1123-1127.

Popliteal Artery to Tibial Plateau Distance

- Yoo, J. H., & Chang, C. B. (2009). The location of the popliteal artery in extension and 90-degree knee flexion measured on MRI. *The Knee*, *16*(2), 143-148.
- Zaidi, S. H., Cobb, A. G., & Bentley, G. (1995). Danger to the popliteal artery in high tibial osteotomy. *Bone and Joint Journal*, *77*(3), 384-386.

