

Javanese Medaka (*Oryzias javanicus* Bleeker, 1854) as Potential Model Organism for Aeromoniasis and Vibriosis Study in Fish

Mohammad Noor Azmai Amal^{1,5*}, Mohd Fauzul Aidil Mohd Roseli¹, Jumria Sutra¹, Syuhada Roslan¹, Siti Nur Khamisah Mazlan¹, Lukman Basri¹, Lee Jing Yie¹, Nurliyana Mohamad¹, Ahmad Ismail¹, Mohd Zamri Saad^{2,5}, Ina Salwany Md Yasin^{3,5} and Nurrul Shaqinah Nasruddin⁴

¹Department of Biology, Faculty of Science, Universiti Putra Malaysia, 43400 UPM Serdang, Selangor, Malaysia

²Department of Veterinary Laboratory Diagnosis, Faculty of Veterinary Medicine, Universiti Putra Malaysia, 43400 UPM Serdang, Selangor, Malaysia

³Department of Aquaculture, Faculty of Agriculture, Universiti Putra Malaysia, 43400 UPM Serdang, Selangor, Malaysia

⁴Centre for Craniofacial Diagnostics and Biosciences, Faculty of Dentistry, Universiti Kebangsaan Malaysia, Jalan Raja Muda Abdul Aziz, 50300 Kuala Lumpur, Malaysia.

⁵Institute of Bioscience, Universiti Putra Malaysia, 43400 UPM Serdang, Selangor, Malaysia

ABSTRACT

Javanese medaka is a small tropical fish that has been widely used as a test organism in ecology, toxicology and ecotoxicology, but less in fish-pathogen related study. This study evaluates the capability of Javanese medaka as an alternative model organism for aeromoniasis and vibriosis study in fish. Javanese medakas were infected with different concentrations of *Aeromonas hydrophila*, *Vibrio alginolyticus* and *V. harveyi* via

intraperitoneal (IP) and immersion (IMM) routes. Following the infections, the LD_{50-240h} of all bacteria to Javanese medaka were observed lower in IP, compared with IMM route. In IP route, the LD_{50-240h} ranged from 2.1×10^4 CFU/mL for *V. harveyi* to 2.5×10^7 CFU/mL for *A. hydrophila*. However, for IMM route, the range was from 6.6×10^7 CFU/mL for *V. harveyi* to 1.1×10^9 CFU/mL for *V. alginolyticus*. The clinical signs, gross lesions and histopathological changes of Javanese medakas infected by either IP or IMM routes of all the pathogens were

ARTICLE INFO

Article history:

Received: 01 March 2019

Accepted: 13 June 2019

Published: 19 August 2019

E-mail addresses:

mnamal@upm.edu.my (Mohammad Noor Azmai Amal)

aismail@upm.edu.my (Ahmad Ismail)

mzamri@upm.edu.my (Mohd Zamri Saad)

salwany@upm.edu.my (Ina Salwany Md Yasin)

shaqinah@ukm.edu.my (Nurrul Shaqinah Nasruddin)

mohdfauzulaidil@gmail.com (Mohd Fauzul Aidil Mohd Roseli)

jumriasutra@gmail.com (Jumria Sutra)

adda0380@gmail.com (Syuhada Roslan)

amiemazlanatwork@gmail.com (Siti Nur Khamisah Mazlan)

lukmanbasriupm@gmail.com (Lukman Basri)

knofez_jyie@hotmail.com (Lee Jing Yie)

m.nurliyana1990@gmail.com (Nurliyana Mohamad)

* Corresponding author

similarly observed in the real host of the pathogen. Moreover, in IP route, most of the fish mortalities (88.9%) were observed within ≤ 120 hours post infection (hpi), while for IMM, most of the mortalities (50.6%) were witnessed beyond 120 hpi, indicating the acute infection for IP compared to IMM route. This study highlights the potential utilization of Javanese medaka as another valuable *in vivo* model organism for bacterial diseases study in fish.

Keywords: Aquaculture, fish diseases, Javanese medaka, test organism

INTRODUCTION

Javanese medaka (*Oryzias javanicus* Bleeker, 1854) is a small tropical fish that has the potential to be used as a test fish, since it showed characteristics similar to the established laboratory fishes (Imai et al., 2007). This species is also used to represent the fresh and marine water fishes, due to its ability to occupy fresh, brackish and saltwater (Inoue & Takei, 2002). Moreover, Javanese medaka has also been widely used as a test organism in ecology, toxicology and ecotoxicology (Aziz et al., 2017; Ferdaus et al., 2018; Ismail & Yusof, 2011; Salleh et al., 2017; Yusof et al., 2012, 2014). Javanese medakas are year-round available, fast in growth rate, hardy to poor water quality, having a short life span and life cycle, easily identified and culturable in the laboratory, and have a wide geographical range (Naruse et al., 2011). This species is widely distributed in Indonesia, Western Borneo, Singapore, Thailand (Magtoon & Termvidchakorn, 2009; Termvidchakorn &

Magtoon, 2008), and along the coastal areas of Peninsular Malaysia (Yusof et al., 2012). However, Javanese medaka is less utilized as a test organism for study of bacterial infection in fish compared with zebrafish (*Danio rerio*) (Bakar et al., 2017; Liu et al., 2015; Neely et al., 2002; Patterson et al., 2012; Phelps et al., 2009; Rodríguez et al., 2008; Schmidt et al., 2017).

Intensification of aquaculture industry has led to various disease outbreaks, especially due to bacterial infections (Ismail et al., 2016, 2017; Toranzo et al., 2005). *Aeromonas hydrophila*, *Vibrio alginolyticus* and *V. harveyi* are among the important pathogens in fresh and marine water fish culture (Haenen et al., 2014; Hossain et al., 2014; Norhariani et al., 2019). Infections of *A. hydrophila*, *V. alginolyticus* and *V. harveyi* are commonly reported in major cultured fishes around the world, such as catfish (*Clarias* spp.), Asian seabass (*Lates calcarifer*) and hybrid grouper (*Epinephelus* spp.) respectively, and cause massive economic losses to the industry worldwide (Azila et al., 2017; Hossain et al., 2014; Ina-Salwany et al., 2018; Nurliyana et al., 2019a, b, c, d; Sharma et al., 2013; Zhu et al., 2017).

In the present study, we describe for the capability of Javanese medaka as an alternative model organism for aeromoniasis and vibriosis study in fish. We demonstrate that Javanese medaka is susceptible following intraperitoneal (IP) and immersion (IMM) challenges by *A. hydrophila*, *V. alginolyticus* and *V. harveyi*. These results constitute a proof of concept study for the use of Javanese medaka in understanding bacterial disease study.

MATERIALS AND METHODS

Ethic Statements

The fish were sampled, handled and sacrificed according to the methods approved by Institutional Animal Care and Use Committee, Universiti Putra Malaysia (AUP No.: R006/2016). All experiments were performed according to the mentioned guidelines and regulations.

Fish Collection and Acclimatization

Javanese medakas were collected from estuary area in Bagan Lalang, Selangor, Malaysia (2°37'15.2"N 101°42'38.4"E). The fish were acclimatized from original salinity level where the fish were captured to final 0 ppt at 1 - 2 ppt/day. The fish were placed in 30 L holding tank with dechlorinated tap water and continuous aeration. The fish were also acclimatized and quarantined for 10 days prior to the experiment. The fish were fed twice daily with commercial brine shrimps and dry foods. Parasitic screening, together with bacterial isolation and identification from 30 randomly selected fish did not reveal any pathogenic organisms.

Bacterial Strains and Preparation

Stock culture of *A. hydrophila* (Saleema, 2015), *V. alginolyticus* (Nehlah et al., 2017) and *V. harveyi* (Ina-Salwany & Nurhidayu, 2015) from previous studies were used. The stock of *A. hydrophila* was cultured in *Aeromonas* medium base agar (AMBA) (Oxoid, Hampshire, United Kingdom) and incubated for 24 h at 30°C. Then, five

colonies of the isolates were inoculated into 10 mL of tryptic soy broth (TSB) (Merck, Darmstadt, Germany) and incubated in an orbital incubator at 0.75 × g for 24 h and at 30°C.

For *V. alginolyticus* and *V. harveyi*, the bacterial stocks were separately cultured on tryptic soy agar (TSA) (Merck) with 1.2% NaCl, and incubated for 24 h at 30°C. Then, five colonies of the isolates were inoculated into 10 mL of TSB with 1.2% NaCl, and incubated in an orbital incubator at 0.75 × g for 24 h and at 30°C.

Experimental Conditions for Fish Challenge Study

A total of 1080 Javanese medakas were used for determination of LD_{50-240h} for IP and IMM routes for *A. hydrophila*, *V. alginolyticus* and *V. harveyi* (180 Javanese medakas for each IP and IMM route, for each bacterial species). During the challenge study, the fish were placed in 6 L aquariums. The static water system was used throughout the study period, while a portion of water was changed daily. Each treatment was conducted in triplicate, including the control group. Every replicate contained 60 fish (10 fish each for five bacterial concentrations and one negative control). The experiments were conducted for 240 h. The freshly dead fish in each treatment group was also collected for bacterial isolation and identification following bacterial challenge.

The mean ± standard deviation (SD) of the total length and weight of the fish prior to the experiments were 1.41 ± 0.23 cm and 0.109 ± 0.091 g, respectively. The

measurements were obtained from 20 randomly sampled fish. The water quality parameters were monitored daily. The mean \pm SD of water temperature ($28.10 \pm 0.10^\circ\text{C}$), pH (7.1 ± 0.7) and dissolved oxygen (5.49 ± 0.08 mg/L) were measured using a hand-held YSI meter (YSI, Yellow Springs, OH, USA), while nitrite (0.12 ± 0.07 mg/L) and ammonia (0.03 ± 0.01 mg/L) were determined using a spectrophotometer (HACH Company, Loveland, CO, USA).

Determination of LD_{50-240h} in IP Route

The bacterial concentrations were calculated based on standard ten-fold serial dilutions and spread plating onto AMBA for *A. hydrophila*, and TSA with 1.2% NaCl for *V. alginolyticus* and *V. harveyi*.

With the exception of the control group, five different bacterial concentrations were used for each IP route challenge (Table 1). The bacterial concentrations ranged as follows: *A. hydrophila* from 2.5×10^5 CFU/mL to 2.5×10^9 CFU/mL, *V. alginolyticus* from 7.0×10^3 CFU/mL to 7.0×10^7 CFU/mL, and *V. harveyi* from 7.0×10^3 CFU/mL to 7.0×10^7 CFU/mL.

The fish were IP-challenged with bacteria according to previous protocols (Phelps et al., 2009; Patterson et al., 2012). Briefly, the fish were anesthetized using MS222 (Sigma-Aldrich, Kuala Lumpur, Malaysia) at the concentration of 0.168 mg/mL (Amal et al., 2018). Then, they were placed with the abdomen facing upwards and supported by a moistened foam bed to ensure that they remained in an upside-down position. A 31G (0.25 mm diameter

and 8 mm length) syringe needle (Terumo, Somerset, NJ, USA) was used to administer 20 μL of the bacterial suspension into the peritoneal cavity of the fish. The needle was inserted into the midline of the abdomen, posterior to the pectoral fins. Only the tip of the needle was inserted into the abdomen of each fish to prevent damage to the internal organs. The LD_{50-240h} was calculated by formulating the regression equations from the percentage of mortality of the fish *versus* the concentrations of the respective bacteria used (Zakari & Kubmarawa, 2016).

Determination of LD_{50-240h} in IMM Route

The bacterial concentrations were calculated as mentioned above. With the exception of the control group, five different bacteria concentrations were used for each IMM route challenge (Table 1). The bacteria concentrations ranged as follows: *A. hydrophila* from 5.6×10^3 CFU/mL to 5.6×10^7 CFU/mL, *V. alginolyticus* from 3.5×10^4 CFU/mL to 3.5×10^8 CFU/mL, and *V. harveyi* from 5.2 CFU/mL to 5.2×10^4 CFU/mL.

For IMM route, prior to the procedures, a 6 L recovery aquarium containing de-chlorinated water was prepared. Ten fish were caught using a sterile fish net and were immersed in their respective bacterial suspension and was left for 2 min. The fish was then transferred into the recovery aquarium to wash off any excessive suspension before transferring them back into their respective post-treatment aquarium with another sterile

fish net to avoid contamination. Prior to the challenge, the fish were anesthetized using MS222 as mentioned above. The LD_{50-240h} was calculated as mentioned above.

Histopathological Assessments

The freshly dead Javanese medakas in each treatment were collected for histopathological assessment. Following fixation in 10% buffered formalin for 24 - 48 h, the fish samples were then processed in tissue processor (Leica TP 1020, Germany), embedded in paraffin, sectioned at 4 µm thick (Leica Jung Multicut 2045, Germany) and stained routinely with Harris haematoxylin and eosin (HE) for

histological study. Complete sections of the fish in each group were examined to detect pathological changes. The photos were recorded and analyzed through microscope Nikon Eclipse 50i Japan and The Nikon NIS-Element D 3.2 Image Analyzer (Nikon Instruments Inc., USA).

RESULTS

Clinical Signs and Gross Lesions of Infected Javanese Medakas

The main clinical signs and gross lesions of Javanese medaka infected by *A. hydrophila*, *V. alginoliticus* and *V. harveyi* are presented in Figures 1 to 3. For *A. hydrophila*, the main observation of the IP and IMM challenged




Figure 1. The main clinical signs and gross lesions of Javanese medakas infected by *Aeromonas hydrophila* following IP and IMM routes including A) inflammation of the dorsal part (red circle) and necrotic caudal fin (red arrow); B) inflammation of the opercular (black circle) and abdominal (red circle) area; C) cloudy eye (red circle) and necrosis of the injection site (red arrow) which only observed in the IP challenged fish; D) necrosis at the edge of anal fin; E) greenish and enlarged of gall bladder; F) occasionally erratic swimming patterns; and G) control fish




Figure 2. The main clinical signs and gross lesions of Javanese medakas infected by *Vibrio alginolyticus* following IP and IMM routes including A) abnormal swimming patterns (red circle); B) necrosis at injection site (red arrow) which only found in the IP challenged fish, and necrosis of caudal and anal fins (black arrow); C) darkening of the abdominal (red circle) and severe necrosis of caudal fin (red arrow); D) hemorrhage of opercular (red circle) and; E) control fish




Figure 3. The main clinical signs and gross lesions of Javanese medakas infected by *Vibrio harveyi* following IP and IMM routes including A) hemorrhage of the body muscle (red arrow); B) hemorrhage of the dorsal body (red arrow); C) darkening of the abdomen (red arrow) and necrosis of caudal fin (red circle); D) hemorrhage of abdomen; E) inflammation of opercular area (red circle); F) isolated, less responsive and lethargic (red circle); G) severe necrosis of caudal fin (red arrow); and H) control fish

fish included occasionally erratic swimming patterns, inflammation of the dorsal, opercular and abdominal areas, necrotic caudal fin, and edge of anal fin, cloudy eye, enlarged gall bladder, and necrosis at the injection site for IP challenged fish only.

For *V. alginolyticus*, the main finding of the IP and IMM challenged fish included abnormal swimming patterns, necrosis of caudal and anal fins, darkening of the abdominal part, hemorrhage of opercula and necrosis at the injection site in the IP challenged fish only. The main abnormalities observed in IP and IMM infected Javanese medaka by *V. harveyi* generally showed similar observation following infection by *V. alginolyticus*, including isolated, less responsive and lethargic, hemorrhage of the body muscle and dorsal body part,

darkening of the abdomen, necrosis of caudal fin, inflammation of the opercular area, and severe necrosis of caudal fin.

LD_{50-240h} and Mortality Patterns Following IP and IMM Challenges

The LD_{50-240h}, mortality patterns and total mortality due to *A. hydrophila*, *V. alginolyticus* and *V. harveyi* in Javanese medakas following IP and IMM challenges up to 240 hpi are presented in Table 1. The LD_{50-240h} of each bacteria in Javanese medakas were lower in IP route, compared with IMM route. For IP challenge, the lowest LD_{50-240h} was observed for *V. harveyi* with 2.1×10^4 CFU/mL, while the highest observed for *A. hydrophila* with 2.5×10^7 CFU/mL, while for IMM challenge, the lowest LD_{50-240h} was also observed for *V.*

Table 1
Mortality patterns, total mortality and LD_{50-240h} of *Aeromonas hydrophila*, *Vibrio alginolyticus* and *V. harveyi* in Javanese medakas following IP and IMM challenges up to 240 hpi

Pathogen concentration (CFU/mL)	Hours post infection										Total mortality	% mortality	
	24	48	72	96	120	144	168	192	216	240			
<i>Aeromonas hydrophila</i>													
Intraperitoneal	LD _{50-240h} = 2.5×10^7 CFU/mL												
Control	0	0	0	0	0	0	0	0	0	0	0	0	0.0
2.5×10^5	6	2	1	0	0	0	0	2	1	0	12	16.0	
2.5×10^6	4	1	0	2	1	1	0	0	1	3	13	43.3	
2.5×10^7	7	1	1	1	0	0	1	1	1	2	15	50.0	
2.5×10^8	5	2	0	2	0	2	0	2	2	1	16	53.3	
2.5×10^9	11	3	0	0	0	2	0	2	1	0	19	63.3	
Immersion	LD _{50-240h} = 3.1×10^8 CFU/mL												
Control	0	0	0	0	0	0	0	0	0	0	0	0	
5.6×10^3	0	0	0	0	1	0	0	1	0	0	2	6.7	
5.6×10^4	0	0	1	0	0	0	1	1	2	0	5	16.7	
5.6×10^5	0	0	2	0	3	0	0	2	0	1	8	26.7	
5.6×10^6	0	0	1	0	2	2	1	2	1	1	10	33.3	
5.6×10^7	0	0	1	0	1	1	3	3	2	2	13	43.3	

Table 1 (continue)

Pathogen concentration (CFU/mL)	Hours post infection										Total mortality	% mortality
	24	48	72	96	120	144	168	192	216	240		
<i>Vibrio alginolyticus</i>												
Intraperitoneal	LD _{50-240h} = 6.3 × 10 ⁵ CFU/mL											
Control	0	0	0	0	0	0	0	0	0	0	0	0.0
7.0 × 10 ³	2	3	1	0	0	0	0	0	0	0	6	20.0
7.0 × 10 ⁴	5	3	1	0	0	0	0	0	0	0	9	30.0
7.0 × 10 ⁵	8	8	2	0	0	0	0	0	0	0	18	60.0
7.0 × 10 ⁶	12	8	1	0	0	0	0	0	0	0	21	70.0
7.0 × 10 ⁷	10	10	1	1	0	0	0	0	0	0	22	73.3
Immersion	LD _{50-240h} = 1.1 × 10 ⁹ CFU/mL											
Control	0	0	0	0	0	0	0	0	0	0	0	0.0
3.5 × 10 ⁴	0	0	0	1	0	0	0	0	0	0	1	3.3
3.5 × 10 ⁵	0	0	1	0	0	0	0	0	0	0	1	3.3
3.5 × 10 ⁶	0	0	1	0	1	0	0	0	0	0	2	6.7
3.5 × 10 ⁷	0	0	1	0	1	0	0	0	0	0	2	6.7
3.5 × 10 ⁸	0	4	1	1	0	0	0	0	0	0	6	20.0
<i>Vibrio harveyi</i>												
Intraperitoneal	LD _{50-240h} = 2.1 × 10 ⁴ CFU/mL											
Control	0	0	0	0	0	0	0	0	0	0	0	0
7.0 × 10 ³	12	3	0	0	0	0	0	0	0	0	15	50.0
7.0 × 10 ⁴	16	0	0	0	0	0	0	0	0	0	16	53.3
7.0 × 10 ⁵	17	0	0	0	0	0	0	0	0	0	17	56.7
7.0 × 10 ⁶	18	5	0	0	0	0	0	0	0	0	23	76.7
7.0 × 10 ⁷	25	1	0	0	0	0	0	0	0	0	26	86.7
Immersion	LD _{50-240h} = 6.6 × 10 ⁷ CFU/mL											
Control	0	0	0	0	0	0	0	0	0	0	0	0
5.2	0	0	0	0	1	1	0	1	0	0	3	10.0
52.0	0	1	0	0	0	0	3	0	0	0	4	13.3
5.2 × 10 ²	0	1	0	0	0	2	1	1	0	0	5	16.7
5.2 × 10 ³	1	1	0	1	1	2	0	0	0	0	6	20.0
5.2 × 10 ⁴	1	1	2	0	1	1	3	1	0	0	10	33.3

harveyi with 6.6 × 10⁷ CFU/mL, while the highest was for *V. alginolyticus* with 1.1 × 10⁹ CFU/mL.

Moreover, in IP route, most of the fish mortalities (88.9%) were observed at ≤ 120 hours post infection (hpi), while in IMM, most of the mortalities (50.6%) were

witnessed beyond 120 hpi. No mortality was recorded for control group either in IP or IMM route for all of the bacterial treatments. *Aeromonas hydrophila*, *V. alginolyticus* and *V. harveyi* were successfully isolated from the freshly dead fish in their respective challenge group either in IP or IMM route.

Histopathological Assessments Following IP and IMM Challenges

Javanese medakas infected with *A. hydrophila* showed moderate meningeal congestion (Figure 4A). Mild glomerulitis was observed with different degrees of hyalinization in the glomeruli (Figure 4B). Formation of cytoplasmic vacuolation within the hepatocytes was observed (Figure 4C). Infiltration of inflammatory cells in between muscle bundle indicating moderate myositis (Figure 4D).

Javanese medakas infected with *V. alginolyticus* displayed moderate meningeal congestion (Figure 5A). However, in *V. harveyi* infection group, congestion of blood vessels in the cerebrum was observed as well, apart from the meningeal congestion (Figure 6A). The kidney of *V. alginolyticus* infection group demonstrated intratubular

hemorrhage (Figure 5C). However, in *V. harveyi* infection group, discrete mild tubular necrosis and moderate atrophic glomeruli can be observed in IP and IMM routes respectively (Figure 6B, 6D). In *V. alginolyticus* infection group, mild hepatic necrosis with diffused pattern was observed (Figure 5B), while multifocal patterns were observed in *V. harveyi* infected group (Figure 6C). Finally, Javanese medakas infected with *V. alginolyticus* displayed increase in MMC formation (Figure 5D). The normal histology of Javanese medakas from negative control groups as presented in Figure 7. The clinical signs, gross lesions and histopathological changes of Javanese medakas following IP and IMM infection by *A. hydrophila*, *V. alginolyticus* and *V. harveyi* as summarized in Table 2.

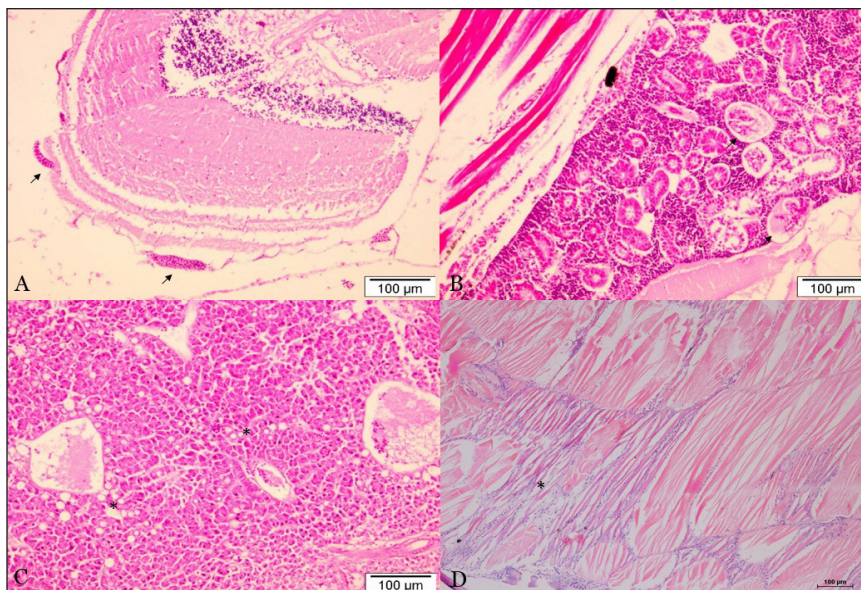


Figure 4. The main histopathological findings of Javanese medakas infected by *Aeromonas hydrophila* through IMM route (A, B, C) and IP route (D). A) Moderate meningeal congestion (arrows), brain, $\times 100$, HE; B) Mild glomerulitis (arrow), kidney, $\times 100$, HE; C) Mild hepatocytes cytoplasmic vacuolation (*), liver, $\times 100$, HE; D) Moderate myositis (*), muscle, $\times 100$, HE

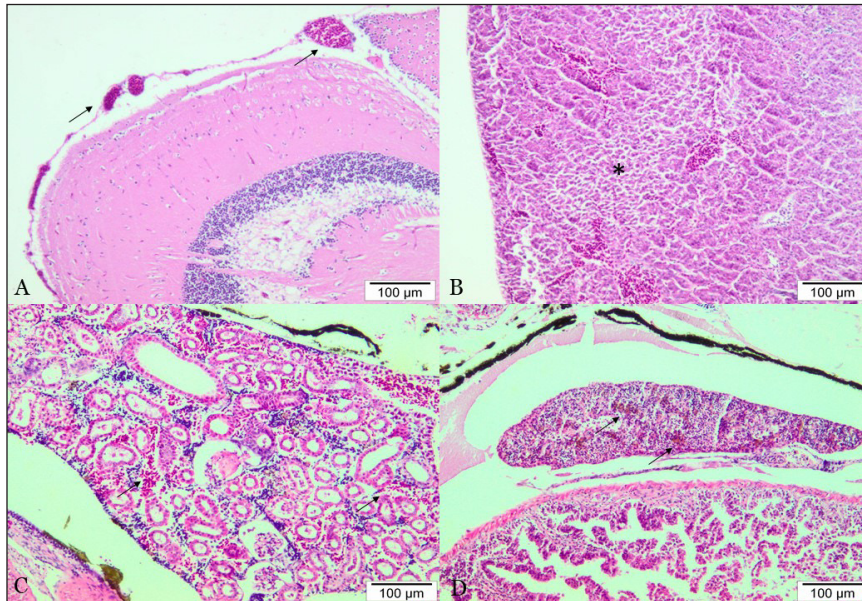


Figure 5. The main histopathological findings of Javanese medakas infected by *Vibrio alginolyticus* through IP route (A, B) and IMM route (C, D). A) Moderate meningeal congestion (arrows), brain, $\times 100$, HE; B) Mild hepatic necrosis (*), liver, $\times 100$, HE; C) Mild renal intratubular hemorrhage (arrows), kidney, $\times 100$, HE; D) Hyper aggregation of splenic melano macrophage centre (MMC) (arrows), spleen, $\times 100$, HE

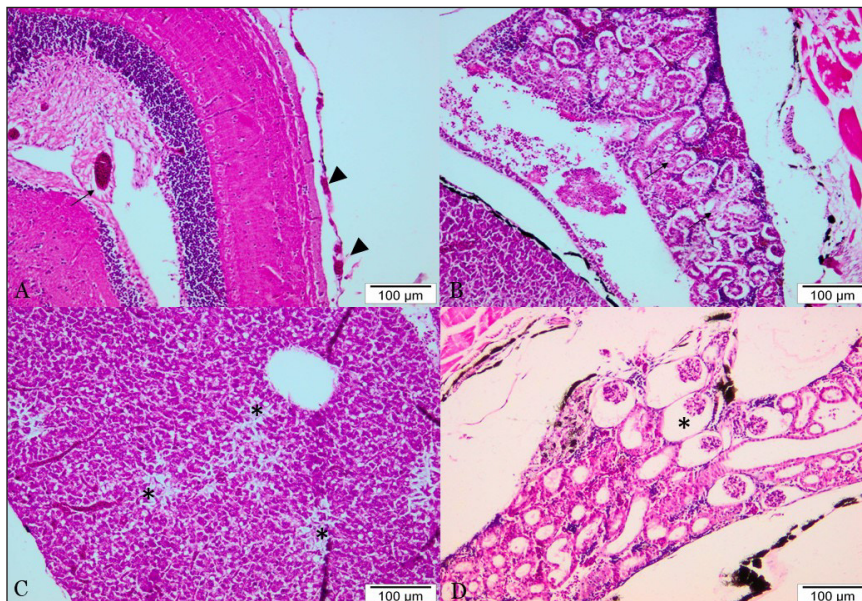


Figure 6. The main histopathological findings of Javanese medakas infected by *Vibrio harveyi* through IP route (A, B) and IMM route (C, D). A) Mild congestion of blood vessels in cerebrum (arrow) and meninges layer (arrow head), brain, $\times 100$, HE; B) Mild tubular necrosis (arrows), liver, $\times 100$, HE; C) Multifocal hepatic necrosis (*), $\times 100$, HE; D) Moderate atrophic glomeruli (*), kidney, $\times 100$, HE

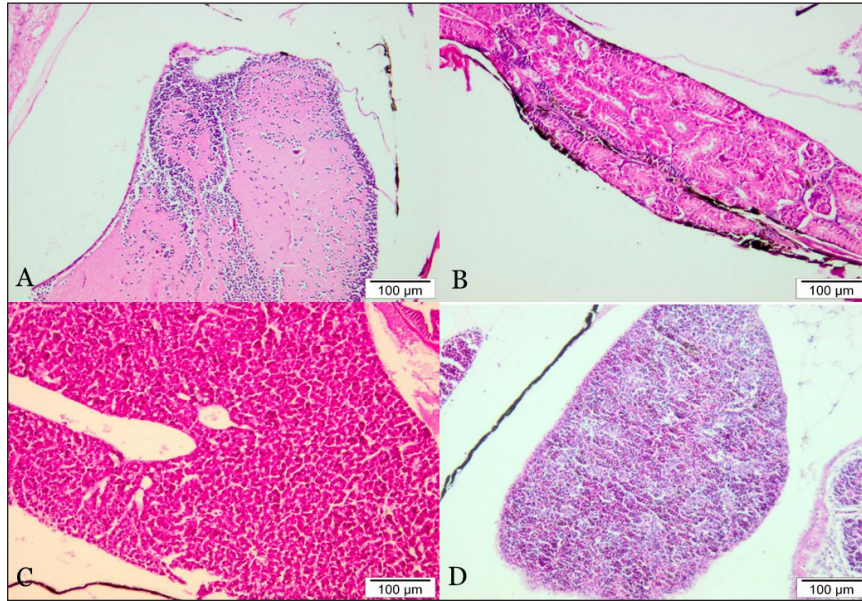


Figure 7. The normal histology of Javanese medakas from negative control groups. A) Brain, ×100, HE; B) Kidney, ×100, HE; C) Liver, ×100, HE; D) Spleen, ×100, HE

Table 2

Summary of clinical signs, gross lesions and histopathological changes of Javanese medakas following IP and IMM infections by *Aeromonas hydrophila*, *V. alginolyticus* and *V. harveyi*

Changes	Pathogen		
	<i>Aeromonas hydrophila</i>	<i>Vibrio alginolyticus</i>	<i>Vibrio harveyi</i>
Clinical signs	<ul style="list-style-type: none"> • Erratic swimming patterns 	<ul style="list-style-type: none"> • Abnormal swimming patterns 	<ul style="list-style-type: none"> • Isolated, less responsive and lethargic
Gross lesions	<ul style="list-style-type: none"> • Inflammation of the dorsal, opercular and abdominal areas • Necrotic of caudal fin and edge of anal fin • Cloudy eye • Greenish and enlarged gall bladder • Necrosis at the injection site for IP challenged fish 	<ul style="list-style-type: none"> • Necrosis of caudal and anal fins • Darkening of the abdominal part • Hemorrhage of opercula • Necrosis at the injection site in the IP challenged fish 	<ul style="list-style-type: none"> • Hemorrhage of the body muscle and dorsal body part • Darkening of the abdomen • Necrosis of caudal fin • Inflammation of the opercular area • Severe necrosis of caudal fin
Histo-pathological changes	<ul style="list-style-type: none"> • Moderate meningeal congestion • Mild glomerulitis was observed with different degrees of hyalinization in the glomeruli • Formation of cytoplasmic vacuolation within the hepatocytes • Infiltration of inflammatory cells in between muscle bundle indicating moderate myositis 	<ul style="list-style-type: none"> • Moderate meningeal congestion • Intratubular hemorrhage of kidney • Mild hepatic necrosis with diffused pattern • Increase in MMC formation 	<ul style="list-style-type: none"> • Congestion of blood vessels in the cerebrum • Meningeal congestion • Mild tubular necrosis and moderate atrophic glomeruli • Mild hepatic necrosis with multifocal patterns

DISCUSSION

Many animal species of interest have been selected as laboratory model organisms. Generally, these organisms were chosen as model animal due to their biological criteria, which are easy to handle and able to represent a bigger group of organisms (Ribas & Piferrer, 2014). Model organisms are usually known as the species of non-human used in the study of biology, to be understood their biological phenomena, thus, other raising models and theories can be applied towards other organisms, predominantly the more complex species compared with the original (Sabrina & Ankeny, 2013).

Medaka has been widely used as the test organism in ecology, genetics, toxicology and ecotoxicology (Kinoshita et al., 2009), but less utilized for fish-pathogen related study (Amal et al., 2018, 2019). In the present study, we discovered the suitability of Javanese medaka as potential model organism for *A. hydrophila*, *V. alginolyticus* and *V. harveyi* infections study. This study revealed that Javanese medaka is susceptible to all of the tested pathogens, causing mortalities and producing lesions typical of the diseases. The clinical signs, gross lesions and histopathological changes of Javanese medakas infected by each of the tested pathogens in this study were similarly observed in the real host of the pathogen and zebrafish (Dias et al., 2016; Laith & Najiah, 2013; Nurliyana et al., 2019c, d; Ransangan & Mustafa, 2009; Tendencia, 2002). This indicates the sensitivity of Javanese medaka to these pathogens and reproducibility of the

infection in the fish, which are important criteria for a model organism (Dietrich et al., 2014).

Natural infection of *A. hydrophila* in catfish (*Clarias. gariepinus*) exhibited gross lesions such as inflammation of the dorsal fin base and body, and necrosis of the caudal fin, anal fin and body (Laith & Najiah, 2013; Saleema, 2015). In its natural host, manifestations of *V. alginolyticus* and *V. harveyi* infections in Asian seabass either as hemorrhagic patches, deep skin and fin ulceration, dark pigmentation, lack of appetite, presence of ascites in the body cavity, enlarged liver and spleen, swimming at the water surface and mortality (Ransangan & Mustafa, 2009; Sharma et al., 2013; Nurliyana et al., 2019c), were similarly observed in Javanese medakas in this study.

Infection of *A. hydrophila* in zebrafish was characterized by the distended visceral cavity and abdominal haemorrhages (Rodríguez et al., 2008). In this study, infection by *A. hydrophila* in Javanese medakas either by IP or IMM route involved muscular lesions, which is considered as classical *Aeromonas* infection (Roberts, 2012). It was believed that *A. hydrophila* used in this study was limited to inducing ulcerative skin lesions, with no hemorrhagic septicemia as in the virulent motile aeromonad septicemia strain (Dias et al., 2016). Experimental infections of *V. alginolyticus* and *V. harveyi* in zebrafish were never studied, however, *V. parahaemolyticus* and *V. anguillarum* infections in zebrafish demonstrated either

hemorrhage of the abdominal cavity and surrounding the injection site (Liu et al., 2015; Paranjpye et al., 2013).

In this study, the LD_{50-240h} of *A. hydrophila* in Javanese medaka was 2.5×10^7 CFU/mL and 3.1×10^8 CFU/mL in IP and IMM route, respectively, higher than observed in IP infected zebrafish at 4.0×10^5 CFU/mL (Rodríguez et al., 2008). However, in piracucu (*Arapaima gigas*), the LD_{50-96h} of *A. hydrophila* was recorded at 1.8×10^8 CFU/mL following intradermal route of infection (Dias et al., 2016). The LD_{50-240h} of *V. alginolyticus* and *V. harveyi* in Javanese medaka following IP and IMM challenges in this study were range from 2.1×10^4 CFU/mL to 6.3×10^5 CFU/mL, and 6.6×10^7 CFU/mL to 1.1×10^9 CFU/mL, while the previous study found that the LD₅₀ of IP infected wild-type zebrafish with *V. parahaemolyticus* was 5.46×10^5 CFU/mL (Paranjpye et al., 2013). In cobia (*Rachycentron canadum*), the LD₅₀ of *V. alginolyticus* was reported at 3.28×10^4 CFU/g fish body weight (Liu et al., 2004), while the LD₅₀ of *V. harveyi* strain VHJR7 in Asian seabass was 1.4×10^4 CFU/g fish body weight (Ransangan et al., 2012). It is suggested that the varied LD₅₀ obtained among the pathogens may explain that each pathogen tested have their own virulence factors, while different hosts also have different immunological reactions towards the pathogens.

The mean of LD_{50-240h} for combined IP and IMM routes for each bacteria suggested that *V. harveyi* ($10^{5.5}$ CFU/mL) was the most pathogenic bacterium in this study, followed by *V. alginolyticus* (10^7 CFU/

mL) and *A. hydrophila* ($10^{7.5}$ CFU/mL). However, in term of the route of infection, IP was considered more acute compared with chronic infection by IMM. This evidence based on the mortality patterns in which 88.9% of the fish mortalities were observed within ≤ 120 hpi in IP route, compared with 50.6% mortalities beyond 120 hpi in IMM route. This observation was similarly reported in zebrafish (Patterson et al., 2012), thus indicating the suitability of Javanese medaka as test organism for the bacterial pathogens.

Histopathological changes of experimentally infected striped catfish (*Pangasianodon hypophthalmus*) with *A. hydrophila* including necrotic hepatocytes, pyknosis, and vacuolation in the liver (Nahar et al., 2016), as similarly observed in this study. Moreover, the histopathological findings in Javanese medaka following *V. alginolyticus* and *V. harveyi* infections are generally similar. Histopathological examination of the Javanese medakas showed congestion, hemorrhage and necrosis in vital organs, especially the brain, liver and kidney. All of these findings were similarly observed in experimental and natural infections of *V. alginolyticus* in Asian seabass (Sharma et al., 2013) and natural infections of *V. harveyi* in Arabic surgeon (*Acanthurus sohal*) (Hashem & El-Barbary, 2013).

CONCLUSION

This study revealed that Javanese medaka was susceptible and sensitive towards IP and IMM infections by *A. hydrophila*, *V.*

alginolyticus and *V. harveyi*. The infections led to typical clinical signs, gross lesions, mortality and produced identical lesions of the diseases as observed in their natural hosts and zebrafish. This study highlights the potential utilization of Javanese medaka as another valuable *in vivo* model organism for bacterial disease studies in fish.

ACKNOWLEDGEMENTS

This study was financially supported by Ministry of Higher Education, Malaysia (FRGS Project No.: FRGS/2/2014/STWN03/UPM/ 02/1).

REFERENCES

- Amal, M. N. A., Ismail, A., Zamri-Saad, M., Ina-Salwany, M. Y., Shaqinah, N. N., Mastor, S. S., ... Nurliyana, M. (2019). Study on *Streptococcus agalactiae* infection in Javanese medaka (*Oryzias javanicus* Bleeker, 1854) model. *Microbial Pathogenesis*, 131(6), 47-52.
- Amal, M. N. A., Zarif, S. T., Suhaiba, M. S., Aidil, M. R. M., Shaqinah, N. N., Zamri-Saad, M., & Ismail, A. (2018). The effect of fish gender on susceptibility to acute *Streptococcus agalactiae* infection in Javanese medaka *Oryzias javanicus*. *Microbial Pathogenesis*, 114(1), 251-254.
- Azila, A., Ramli, R., Ridzuan, M. S. M., Murni, M., Hashim, S., Sudirwan, F., ... Amal, M. N. A. (2017). The presence of *Vibrionaceae*, *Betanodavirus* and *Iridovirus* in marine cage-cultured fish: Role of fish size, water physicochemical parameters and relationships among the pathogens. *Aquaculture Reports*, 7(8), 57-65.
- Aziz, F. Z. A., Zulkifli, S. Z., Mohamat-Yusof, F., Amal, M. N. A., & Ismail, A. (2017). Histological study on mercury-induced gonadal impairment in Javanese medaka (*Oryzias javanicus*). *Turkish Journal of Fisheries and Aquatic Sciences*, 17(3), 621-627.
- Bakar, N. A., Sata, N. S. A. M., Ramlan, N. F., Ibrahim, W. N. W., Zulkifli, S. Z., Abdullah, C. A. C., ... Amal, M. N. A. (2017). Evaluation of the neurotoxic effects of chronic embryonic exposure with inorganic mercury on motor and anxiety-like responses in zebrafish (*Danio rerio*) larvae. *Neurotoxicology and Teratology*, 59(1-2), 53-61.
- Bleeker, P. (1854). Ichthyologische waarnemingen, gedaan op verschillende reizen in de Residentie Banten [Ichthyological observations made on different journeys in the Residence Banten]. *Natuurkundig Tijdschrift voor Nederlandsch Indië*, 7, 309-326.
- Dias, M. K. R., Sampaio, L. S., Proietti-Junior, A. A., Yoshioka, E. T. O., Rodrigues, D. P., Rodriguez, A. F. F., ... Tavares-Dias, M. (2016). Lethal dose and clinical signs of *Aeromonas hydrophila* in *Arapaima gigas* (Arapaimidae), the giant fish from Amazon. *Veterinary Microbiology*, 188(5), 12-15.
- Dietrich, M. R., Ankeny, R. A., & Chen, P. M. (2014). Publication trends in model organism research. *Genetics*, 198(3), 787-794.
- Ferdaus, M. Y., Sarah-Nabila, A. G., Syaizwan, Z. Z., Amal, M. N. A., Wan-Norhamidah, W. I., Yusof, S., & Ismail, A. (2018). Acute toxicity test of copper pyrithione on Javanese medaka and the behavioural stress symptoms. *Marine Pollution Bulletin*, 127(2), 150-153.
- Haenen, O. L. M., Fouz, R. B., Amaro, G. C., Isern, M. M., Mikkelsen, H., Zrnčić, S., ... Dalsgaard, I. (2014). Vibriosis in aquaculture. *Bulletin of the European Association of Fish Pathologists*, 34(4), 138-147.
- Hashem, M., & El-Barbary, M. (2013). *Vibrio harveyi* infection in Arabian surgeon fish (*Acanthurus sohal*) of Red Sea at Hurgada, Egypt. *Egyptian Journal of Aquatic Research*, 39(3), 199-203.

- Hossain, M. J., Sun, D., McGarey, D. J., Wrenn, S., Alexander, L. M., Martino, M. E., ... Liles, M. R. (2014). An Asian origin of virulent *Aeromonas hydrophila* responsible for disease epidemics in United States-farmed catfish. *mBio*, 5(3), e00848-14.
- Imai, S., Koyama, J., & Fujii, K. (2007). Effects of estrone on full life cycle of Java medaka (*Oryzias javanicus*), a new marine test fish. *Environmental Toxicology and Chemistry*, 26(4), 726-731.
- Ina-Salwany, M. D., & Nurhidayu, A. S. (2015). A prospect of using *Vibrio harveyi* isolated from the intestine of healthy farmed tiger grouper, *Epinephelus fuscoguttatus* (Forsskål, 1775) as probiotics. *CIBTech Journal of Biotechnology*, 4(3), 25-35.
- Ina-Salwany, M. Y., Al-saari, N., Mohamad, A., Fathin-Amirah, M., Mohd, A., Amal, M. N. A., ... Zamri-Saad, M. (2018). Vibriosis in fish: A review on disease development and prevention. *Journal of Aquatic Animal Health*, 31(1), 3-22.
- Inoue, K., & Takei, Y. (2002). Diverse adaptability in *Oryzias* species to high environmental salinity. *Zoological Science*, 19(7), 727-734.
- Ismail, A., & Yusof, S. (2011). Effect of mercury and cadmium on early life stages of Java medaka (*Oryzias javanicus*): A potential tropical test fish. *Marine Pollution Bulletin*, 63(5-12), 347-349.
- Ismail, M. S., Siti-Zahrah, A., Syafiq, M. R. M., Amal, M. N.A., Firdaus-Nawi, M., & Zamri-Saad, M. (2016). Feed-based vaccination regime against streptococcosis in red tilapia, *Oreochromis niloticus* × *Oreochromis mossambicus*. *BMC Veterinary Research*, 12(1), 194.
- Ismail, M. S., Syafiq, M. R., Siti-Zahrah, A., Fahmi, S., Shahidan, H., Hanan, Y., ... Zamri-Saad, M. (2017). *Fish and Shellfish Immunology*, 60(1), 21-24.
- Kinoshita, M., Murata, K., Naruse, K., & Tanaka, M. (2009). *Medaka: Biology, management and experimental protocols*. Hoboken, USA: Wiley-Blackwell.
- Laith, A. R., & Najiah, M. (2013). *Aeromonas hydrophila*: Antimicrobial susceptibility and histopathology of isolates from diseased catfish, *Clarias gariepinus* (Burchell). *Journal of Aquaculture Research and Development*, 5(2), 1-7.
- Liu, P. C., Lin, J. Y., Hsiao, P. T., & Lee, K. K. (2004). Isolation and characterization of pathogenic *Vibrio alginolyticus* from diseased cobia *Rachycentron canadum*. *Journal of Basic Microbiology*, 44(1), 23-28.
- Liu, X., Wu, H., Liu, Q., Wang, Q., Xiao, J., & Zhang, Y. (2015). Skin-injured zebrafish, *Danio rerio*, are more susceptible to *Vibrio anguillarum* infection. *Journal of the World Aquaculture Society*, 46(3), 301-310.
- Magtoon, W., & Termvidchakorn, A. (2009). A revised taxonomic account of ricefish *Oryzias* (Belontiiformes; Adrianichthyidae), in Thailand, Indonesia and Japan. *Natural History Journal of Chulalongkorn University*, 9(1), 35-68.
- Nahar, S., Rahman, M. M., Ahmed, G. U., & Faruk, M. A. R. (2016). Isolation, identification, and characterization of *Aeromonas hydrophila* from juvenile farmed pangasius (*Pangasianodon hypophthalmus*). *International Journal of Fisheries and Aquatic Studies*, 4(4), 52-60.
- Naruse, K., Minoru, T., & Hiroyuki, T. (2011). *Medaka: A model for organogenesis, human disease, and evolution*. Tokyo, Japan: Springer.
- Neely, M. N., Pfeifer, J. D., & Caparon M. (2002). *Streptococcus-zebrafish* model of bacterial pathogenesis. *Infection and Immunity*, 70(7), 3904-3914.
- Nehlah, R., Firdaus-Nawi, M., Nik Haiha, N. Y., Karim, M., Zamri-Saad, M., & Ina-Salwany M. Y. (2017). Recombinant vaccine protects juvenile hybrid grouper, *Epinephelus fuscoguttatus* ×

- Epinephelus lanceolatus*, against infection by *Vibrio alginolyticus*. *Aquaculture International*, 25(6), 2047-2059.
- Norhariani, M. N., Siti-Hajar, M. Y., Hassan, M. D., Amal, M. N. A., & Nurliyana, M. (2019). Costs of management practices of Asian seabass (*Lates calcarifer* Bloch, 1790) cage culture in Malaysia using stochastic model that include uncertainty in mortality. *Aquaculture*, 510, 347-352. doi: 10.1016/j.aquaculture.2019.04.042
- Nurliyana, M., Amal, M. N. A., Zamri-Saad, M., & Ina-Salwany, M. Y. (2019a). Possible transmission routes of *Vibrio* spp. in tropical cage-cultured marine fishes. *Letters in Applied Microbiology*, 68(6), 485-496.
- Nurliyana, M., Amal, M. N. A., Zamri-Saad, M., Ina-Salwany, M. Y., Nor-Amalina, Z., Muskhazli, M., & Shaqinah, N. N. (2019b). Virulence-associated genes and antibiotic resistance patterns of *Vibrio* spp. isolated from cultured marine fishes in Malaysia. *BMC Veterinary Research*, 2019(15), 176.
- Nurliyana, M., Fauzul-Aidil, M. R., Amal, M. N. A., Zamri-Saad, M., Ina-Salwany, M. Y., Nor-Amalina, Z., & Shaqinah, N. N. (2019c). Natural concurrent infection of *Vibrio harveyi* and *V. alginolyticus* in cultured hybrid groupers in Malaysia. *Journal of Aquatic Animal Health*, 31(1), 88-96.
- Nurliyana, M., Muskhazli, M., Amal, M. N. A., Zamri-Saad, M., Ina-Salwany, M. D., & Nurhidayu, A. (2019d). Environmental factors associated with the presence of Vibrionaceae in tropical cage-cultured marine fishes. *Journal of Aquatic Animal Health*, 31(2), 154-167. doi: 10.1002/aah.10062.
- Paranjpye, R. N., Myers, M. S., Yount, E. C., & Thompson, J. L. (2013). Zebrafish as a model for *Vibrio parahaemolyticus* virulence. *Microbiology*, 159(12), 2605-2615.
- Patterson, H., Saralahti, A., Parikka, M., Dramsi, S., Trieu-Cuot, P., Poyart, C., ... Rämetsä, M. (2012). Adult zebrafish model of bacterial meningitis in *Streptococcus agalactiae* infection. *Developmental and Comparative Immunology*, 38(3), 447-455.
- Phelps, H. A., Runft, D. L., & Neely, M. N. (2009). Adult zebrafish model of streptococcal infection. *Current Protocols in Microbiology*, 13(5), 9D-1.
- Ransangan, J., & Mustafa, S. (2009). Identification of *Vibrio harveyi* isolated from diseased Asian seabass (*Lates calcarifer*) by use of 16S ribosomal DNA sequencing. *Journal of Aquatic Animal Health*, 21(3), 150-155.
- Ransangan, J., Lal, T. M., & Al-Harbi, A. H. (2012). Characterization and experimental infection of *Vibrio harveyi* isolated from diseased Asian seabass (*Lates calcarifer*). *Malaysian Journal of Microbiology*, 8(2), 104-115.
- Ribas, L., & Piferrer, F. (2014). The zebrafish (*Danio rerio*) as a model organism, with emphasis on applications for finfish aquaculture research. *Reviews in Aquaculture*, 6(4), 209-240.
- Roberts, R. J. (2012). *The bacteriology of teleosts*. Oxford, United Kingdom: Wiley-Blackwell.
- Rodríguez, I., Novoa, B., & Figueras A. (2008). Immune response of zebrafish (*Danio rerio*) against a newly isolated bacterial pathogen *Aeromonas hydrophila*. *Fish and Shellfish Immunology*, 25(3), 239-249.
- Sabrina, L., & Ankeny, R. A. (2013). What makes a model organism?. *Endeavour*, 37(4), 209-212.
- Saleema, M. (2015). *Molecular characterization of Aeromonas hydrophila and development of recombinant cells vaccine expressing outer membrane proteins against its in African catfish (Clarias gariepinus Burchell)* (Unpublished Master thesis), Universiti Putra Malaysia, Malaysia.

- Salleh, A. F. M., Amal, M. N. A., Shaqinah, N. N., Syaizwan, Z. Z., Ferdaus M. Y., Ibrahim, W. N. W., & Ismail, A. (2017). Water pH effects on survival, reproductive performances and ultrastructure of gonads, gills and skins of Javanese medaka (*Oryzias javanicus*). *Turkish Journal of Veterinary and Animal Sciences*, 41(4), 471-481.
- Schmidt, J. G., Korbut, R., Ohtani, M., & Jørgensen, L. V. G. (2017). Zebrafish (*Danio rerio*) as a model to visualize infection dynamics of *Vibrio anguillarum* following intraperitoneal injection and bath exposure. *Fish and Shellfish Immunology*, 67(8), 692-697.
- Sharma, S. R. K., Rathore, G., Verma, D. K., Sadhu, N., & Philipose, K. K. (2013). *Vibrio alginolyticus* infection in Asian seabass (*Lates calcarifer*, Bloch) reared in open sea floating cages in India. *Aquaculture Research*, 44(1), 86-92.
- Tendencia, E. A. (2002). *Vibrio harveyi* isolated from cage-cultured seabass *Lates calcarifer* Bloch in the Philippines. *Aquaculture Research*, 33(6), 455-458.
- Termvidchakorn, A., & Magtoon, W. (2008). Development and identification of the ricefish *Oryzias* in Thailand. *ScienceAsia*, 34(4), 416-423.
- Toranzo, A. E., Magariños, B., & Romalde, J. L. (2005). A review of the main bacterial fish diseases in mariculture systems. *Aquaculture*, 246(1-4), 37-61.
- Yusof, S., Ismail, A., & Alias, M. S. (2014). Effect of glyphosate-based herbicide on early life stages of Java medaka (*Oryzias javanicus*): A potential tropical test fish. *Marine Pollution Bulletin*, 85(2), 494-498.
- Yusof, S., Ismail, A., Koito, T., Kinoshita, M., & Inoue, K. (2012). Occurrence of two closely related ricefishes, Javanese medaka (*Oryzias javanicus*) and Indian medaka (*O. dancena*) at sites with different salinity in Peninsular Malaysia. *Environmental Biology of Fishes*, 93(1), 43-49.
- Zakari, A., & Kubmarawa, D. (2016). Acute toxicity (LD₅₀) studies using Swiss albino mice and brine shrimp lethality (LC₅₀ and LC₉₀) determination of the ethanol extract of stem bark of *Echinaceae angustifolia* DC. *Natural Products Chemistry and Research*, 4(6), 1-6.
- Zhu, Z. M., Dong, C. F., Weng, S. P., & He, J. G. (2017). The high prevalence of pathogenic *Vibrio harveyi* with multiple antibiotic resistance in scale drop and muscle necrosis disease of the hybrid grouper, *Epinephelus fuscoguttatus* (♀) × *E. lanceolatus* (♂), in China. *Journal of Fish Diseases*, 41(4), 589-601.

